



# International Journal of Health Care and Biological Sciences

Case Study

Open Access

A Case Study on Spinal Osteoarticular Tuberculosis (Pott's disease): A Case Study Analysis

B.Chaitanya<sup>1</sup>, Ch.Pallavi<sup>2</sup>, D. Anusha<sup>\*3</sup>

<sup>1</sup> Associate Professor, Department of Pharmaceutical Analysis, Avanthi institute of pharmaceutical sciences

<sup>2</sup> Assistant Professor, Aditya College of Pharmacy

<sup>3</sup> Avanthi Institute of Pharmaceutical Sciences, Cherukupally, Vizianagaram, Andhra Pradesh.

## Article History

Received on: 11-04-2021

Revised On : 25-05-2021

Accepted on : 15-06-2021

**Keywords:** spinal osteoarticular tuberculosis (TB), extrapulmonary tuberculosis, rehabilitation, effective management.

## Abstract

This case study explores the presentation, diagnosis, treatment, and rehabilitation of a patient diagnosed with spinal osteoarticular tuberculosis (TB). Spinal TB, a rare but severe form of extrapulmonary tuberculosis, often presents with nonspecific symptoms, making early diagnosis challenging. The case highlights the importance of a multidisciplinary approach involving radiology, pathology, and clinical expertise for timely and effective management.



This article is licensed under a Creative Commons Attribution-Non Commercial 4.0 International License. Copyright © 2021 Author(s) retain the copyright of this article.



## \*Corresponding Author

Ch.Pallavi

Hosted by

saap.org.in

## Introduction

Spinal osteoarticular tuberculosis is a form of musculoskeletal tuberculosis that primarily affects the vertebral column. The disease is caused by Mycobacterium tuberculosis and poses a significant health challenge due to its potential to cause severe neurological deficits and spinal deformities known as kyphosis (hunchback) [1]. If left untreated. Spinal TB is

also known as tuberculous spondylitis or Pott's disease [1]. Some symptoms like severe back pain Tenderness in the back area, Spinal deformity, Muscle spasms,

restricted motion of the spine, Neurological deficits the epidemiology of tuberculosis is caused by factors which include socio-economic

- Development, way of life, geographical location, and accessibility to medical services [2].
- Spinal tuberculosis is rare in the UK (notified cases have an incidence rate of 8.4 per 100,000 population) [3] but elsewhere it represents about 50% of musculoskeletal tuberculosis [4].
- Spinal tuberculosis accounts for around 1% of all cases of tuberculosis and around 15% of extrapulmonary tuberculosis cases [5].

## Associated Co-morbidities

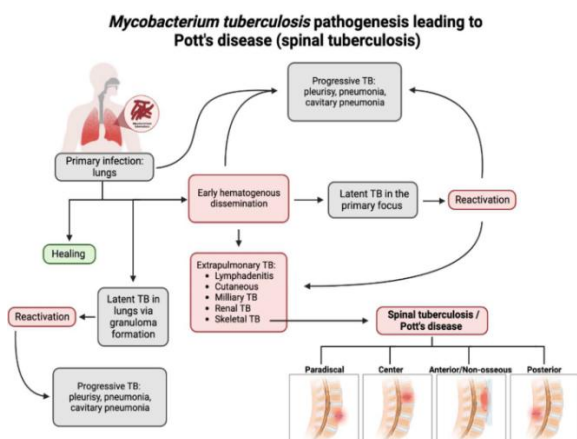
Include: Immunosuppressive Disorders; HIV/AIDS; TB; Gastrectomy; Peptic Ulcer; Drug Addiction; Alcoholism; Malnourishment; Low Socioeconomic Status [6].

## Pathophysiology

Spinal tuberculosis is typically caused by hematogenous dissemination from a primary site of infection (most commonly the lungs). Because the paradiscal arteries often supply the subchondral bone on either side of the disc space, this is the most prevalent site of vertebral involvement. The other patterns of involvement include central (with predominant vertebral body involvement), posterior (involving the posterior structures primarily) and non-osseous involvement (presenting with the abscess). [7][8] Progressive vertebral destruction leads to spinal kyphotic deformity and instability.

## Case Presentation

A 53-year-old male presented with a 6-month history of progressive back pain, weakness in the lower limbs, and occasional fever and diabetic. Clinical examination revealed tenderness over the lumbar spine and reduced muscle strength in the lower extremities. Initial radiographs showed evidence of vertebral destruction at the L4-L5 level. Under the treatment for diabetes.



## Diagnosis

To confirm the diagnosis, a combination of imaging studies, laboratory tests, and pathological examinations was conducted. Magnetic resonance imaging (MRI) revealed characteristic features such as vertebral body destruction, paravertebral abscess formation, and spinal cord compression. Additionally, a tuberculin skin test, and chest X-ray, The definitive diagnosis was established through a biopsy of the affected vertebral tissue, confirming the presence of acid-fast bacilli.

## Treatment

The patient was promptly initiated on a multidrug antitubercular therapy (ATT) regimen, including isoniazid, rifampicin, ethambutol, and pyrazinamide. Anti-inflammatory medications were prescribed to manage pain and reduce inflammation. Surgical intervention, in the form of decompressive laminectomy

and abscess drainage, was performed to alleviate spinal cord compression and stabilize the affected vertebral segment. anti-diabetic drugs are given and surgery is carried out after the body blood sugar was controlled.

## Rehabilitation

Postoperative rehabilitation focused on restoring functional independence and preventing complications. Physical therapy included mobility exercises, core strengthening, and gait training. Close monitoring of medication adherence and regular follow-ups with the infectious disease specialist were essential components of the rehabilitation process.

## Outcome

The patient showed significant improvement in symptoms after completion of the intensive phase of antitubercular therapy. Follow-up imaging revealed resolution of the spinal lesions and abscess. The patient regained full muscle strength and was able to resume daily activities with minimal assistance.

## Discussion

This case challenges in diagnosing spinal osteoarticular tuberculosis and importance of a comprehensive diagnostic approach. Timely initiation of anti tubercular therapy and surgical intervention, when necessary, are crucial for improving outcomes and preventing complications. Multidisciplinary collaboration between orthopedic surgeons, infectious disease specialists, and rehabilitation professionals is essential for optimal patient care.

## Conclusion

Spinal osteoarticular tuberculosis is a rare but potentially debilitating condition that requires prompt diagnosis and a multidisciplinary approach for effective management. This case study illustrates the importance of integrating clinical, radiological, and pathological findings to achieve accurate diagnosis and highlights the success of a comprehensive treatment and rehabilitation plan in restoring the patient's health and function.

## References

1. <https://www.medanta.org/the-rare-but-alarming-spinal-tb-and-its-complications>
2. (Zeng H, Liang Y, He J, et al; Analysis of Clinical Characteristics of 556 Spinal Tuberculosis Patients in Two Tertiary Teaching Hospitals in Guangxi Province. Biomed Res Int. 2021 Dec 10;2021:1344496. doi: 10.1155/2021/1344496. eCollection 2021.

3. Tuberculosis; NICE CKS, January 2019 (UK access only)
4. Shikhare SN, Singh DR, Shimpi TR, et al; Tuberculous osteomyelitis and spondylodiscitis. *Semin MusculoskeletRadiol*. 2011 Nov15(5):446-58. doi: 10.1055/s-0031-1293491. Epub 2011 Nov 11.
5. Chipeio ML, Sayah A, Hunter CJ; Spinal Tuberculosis. *Am J Trop Med Hyg*. 2021 Mar 15104(5):1605-1606. doi: 10.4269/ajtmh.20-1529.)
6. [https://www.physio-pedia.com/Pott%27s\\_Disease](https://www.physio-pedia.com/Pott%27s_Disease)
7. Goni V, Thapa BR, Vyas S, Gopinathan NR, Rajan Manoharan S, Krishnan V. Bilateral psoas abscess: atypical presentation of spinal tuberculosis. *Arch Iran Med*. 2012 Apr;15(4):253-6. [PubMed]
8. Rajasekaran S, Kanna RM, Shetty AP. Pathophysiology and Treatment of Spinal Tuberculosis. *JBJS Rev*. 2014 Sep 23;2(9) [PubMed]