



International Journal of Health Care and Biological Sciences


Case Report

Open Access

A case report on pemphigus foliaceus

Divyasree Muppineni*, Vishnu Sree Uppu, Dr. Shaik Firoz

Department of Pharmacy Practice, QIS College of Pharmacy, Ongole, Prakasam District, Andhra Pradesh, India – 523001

Article History	Abstract
Received on: 25-05-2021 Revised On : 08-07-2021 Accepted on : 13-07-2021	Pemphigus Foliaceus (PF) is second most common autoimmune vesicular disease in the pemphigus family characterized through superficial blisters of the skin and infrequently mucous membranes which breach to produce scaly, crusted lesions. A 54 year old female patient admitted in female derma ward in tertiary care hospital, with the chief complaints of painful ruptured blisters all over the body with crusty, scaly patches associated with serous discharge and itching since 15 days. A positive Nikolsky's sign is when the skin shears off easily when the surface is wiped sideways with a cotton swab or a finger. Based on both subjective and objective evidence, this case is assessed as Pemphigus Foliaceus. The plan includes Corticosteroids, Immunosuppressants, Antibiotics, Vitamin A & D supplements, IV fluids, calcium and aminoacids supplements, antivirals and antifungals (if needed), proper wound management and finally plasmapheresis.
Keywords: Pemphigus Vulgaris, Pemphigus Foliaceus, Nikolsky's-sign, corticosteroid-immunosuppressants. DOI: https://doi.org/10.46795/ijhcb.v2i3.207 	

This article is licensed under a Creative Commons Attribution-Non Commercial 4.0 International License. Copyright © 2021 Author(s) retain the copyright of this article.



*Corresponding Author

Divyasree Muppineni

Email: divyasreemuppineni1998@gmail.com

Hosted by

saap.org.in

Introduction

The word Pemphigus stems after the Greek 'pemphix', which means blister or bubble, and it describes a cluster of IgG-mediated autoimmune diseases, where chronic blistering of stratified squamous epithelial diseases of skin and oral mucosa results in the production of IgG auto-antibodies beside extracellular domains of cell membrane proteins of keratinocytes results in acantholysis (the damage of cell-cell adhesion between keratinocytes) causes blisters and erosions [1]. Generally, immune system produces antibodies to combat off harmful invaders, such as viruses and bacteria. But in Pemphigus, the body produces antibodies that

damage cells of skin and mucous membranes. Pemphigus is not transmittable, in most cases the triggering factor is unknown. Rarely, pemphigus is triggered by exposure to sun, insect bites (Fogo selvagem), the use of angiotensin-converting enzyme inhibitors, penicillamine, Angiotensin-II receptor blockers, NSAIDs, Antibiotics and other drugs [2]. In pemphigus, IgG autoantibodies are typically directed against desmogleins (desmoglein 1 and desmoglein 3), which are portion of the cadherin family of cell-cell adhesion molecules that are found in desmosomes, which are the structures mainly responsible for retaining intercellular adhesion in stratified squamous epithelia, such as the skin and oral mucosa [3,4]. Epidemiologically, the occurrence of Pemphigus varied worldwide from 0.09% to 2%. Pemphigus is more common in Jews and in people of Mediterranean descent and from Middle East. Incidence approximations of pemphigus considerably vary around the world [5]. Pemphigus vulgaris is the furthestmost

common subtype of pemphigus in Europe, the United States and Japan it preferentially affects women, and most of the patients are 50–60 years of age at disease onset [5,6]. In India Pemphigus arises in earlier age group (<45 years) as compared to western country. Male to female proportion is almost identical with limited studies presenting female predominance [7].

Classification

Pemphigus has three foremost subtypes as followed

- Pemphigus Vulgaris,
- Paraneoplastic Pemphigus and
- Pemphigus Foliaceus.

Pemphigus Vulgaris

Pemphigus vulgaris is the most common type of pemphigus. Blisters usually first appear on the mouth. The blisters do not cause itch, but they are painful. Blisters may then appear on the skin and sometimes on the genitals.

Paraneoplastic Pemphigus

A identical rare kind of pemphigus that arises in people with some cancers is called Paraneoplastic pemphigus. The blisters and sores might appear on the mouth, lips and skin. This form may also cause scars on the eyelids and eyes. It can also result in lung problems.

Pemphigus Foliaceus

Pemphigus Foliaceus is part of the pemphigus set of autoimmune illnesses. Autoimmune diseases results once the body's immune system assaults healthy tissue. In Pemphigus Foliaceus, the immune system harms skin cells termed keratinocytes. Pemphigus Foliaceus [PF] causes blisters, cuts, in addition crusty spots on the skin. The sores can be aching and unpleasant, but PF is a fairly benign health condition that does not characteristically cause other health problems. The immune system produces antibodies that attach to a protein called desmoglein-1 in an individual with PF. This protein is positioned in sticky spots on skin cells named desmosomes. When the antibodies attach to this protein, it causes the skin cells to disperse from one another, which causes the skin to blister and peel [11].

Diagnosis done on physical examination, positive nikolsky's sign, Tzanck test, performing biopsy, or blood test to measure levels of pemphigus antibodies, and endoscopy. Fatal and severe complications of pemphigus vulgaris can be seen. They can be skin infections, sepsis, or the spread of infection through the bloodstream, dehydration. Treatment measures include use of corticosteroids, steroid-sparing

immunosuppressants, Dapsone, IV immunoglobulins, Rituximab, plasmapheresis, and proper wound management [10].

Case Report

A 54 year old female patient presented to female dermatology ward with complaints of painful ruptured blisters all over the body with crusty, scaly patches associated with serous discharge and itching since 15 days. She had past history of similar complaints 6 years ago for which she undergone treatment and the physician advised her to avoid exposure of dung and dust. Her symptoms subsided within 45 days subsequently taking the therapy and avoiding exposure to dung and dust. 15 days back She was diagnosed as diabetic and on medication, and medication includes insulin 10U and 8U. A positive Nikolsky's sign is also observed which is a physical evidence for Pemphigus Foliaceus and laboratory data revealed a slight increase in FBS [140mg/dl] & RBS [173mg/dl]. Based on subjective evidence and past history the case is assessed as Pemphigus Foliaceus. Her plan include Inj. Dexamethasone 2cc [8mg/2ml], Inj. Ceftriaxone [1gm/5ml], Cap. Cyclophosphamide[25mg], Cap. vitamin-A&D, Tab Cetirizine [10mg], Neomyin [Neomycin-Polymyxin] face cream, Inj. Insulin [10U-8U], Inj. Amino acids, IV fluids, Inj. Pantoprazole[40mg], and proper wound management.

Discussion

Pemphigus Foliaceus shows fluid-filled blisters to form on skin, often on chest, back, and shoulders. At first the blisters are minor, but they progressively develop and increase in number. Eventually they can cover whole trunk, face, and scalp. The blisters breakdown and open easily. Fluid may emit from them. If rubbed, the whole top layer can separate from the bottom later and peel off in a sheet. After the blisters break open, they can form sores. The sores scale and crust over. Although Pemphigus Foliaceus generally is not throbbing, but may feel pain or burning sensation in the area of the blisters and also itch. In this state, antibodies bind to a protein in the superficial layer of skin, termed epidermis. This layer of skin cells are called keratinocytes. These cells produce the protein called keratin that provides structure and support to skin. When antibodies outbreak keratinocytes, they separate. Fluid fills the spaces they leave behind.

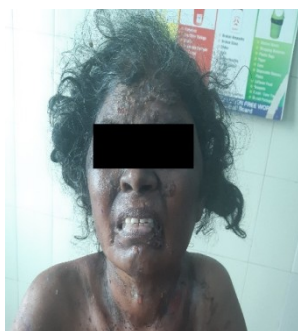

Fig 01:

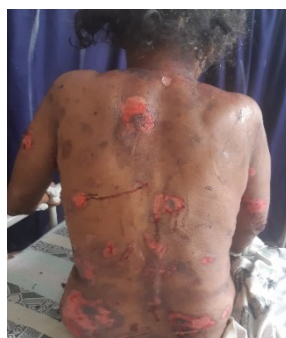

Fig 02:

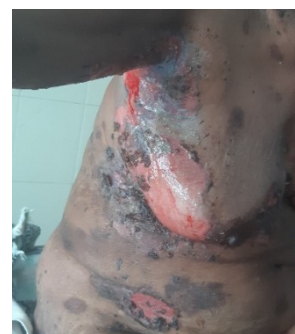

Fig 03:

produces the blisters and erosions on the skin[8]. Another type is Pemphigus erythematosus is a type of Pemphigus Foliaceus that causes blisters to form only on the face. People with lupus are more oftenly affected [9].

In this case patient initially developed fluid filled blisters all over the body associated with pain and itching since 15 days. Later these blisters bursted leading to painful crusty and scaly hypopigmented patches involving almost all the body parts. She had similar history 6 years back. 3 years back she again started exposure to dung and dust which leads to relapse of symptoms. Small fluid filled blisters were seen since 1 month and the blisters started bursting with the involvement of most of the body parts. Based on her past history and physical evidence this case was diagnosed as Pemphigus Foliaceus. Under physician's suggestion she was kept on pulse therapy which includes corticosteroids and immunosuppressants along with antihistamine and antibiotics as mentioned in treatment plan. For blisters, she was treated with soothing lotion, wet dressings and advised to abstain from too much exposure to sun, avoiding acidic foods that may irritate blisters. By 7th day she got relief from painful and itching of blisters and lesions.

Conclusion

Pemphigus Foliaceus is an auto-immune disease of pemphigus group of disorders. The much rarer Pemphigus Foliaceus is notoriously difficult to diagnose because the blisters are not as obvious and leafy scales and crusts predominate. Cure is accurate for Pemphigus Foliaceus but proper precautions are the must to avoid prognosis of the disease.

Acknowledgement

We are grateful to the hospital administration of GGH, Ongole in allowing us to report the case in to the hospital. Thanks for the support provided by hospital

head of the department Dr.D.Sree Ramulu. We would like to thank the patient and her attenders for accepting our request and giving their support in providing all details as requested.

References

1. Michael Kasperkiewicz, Christoph T. Ellebrecht, Hayato Takahashi, Jun Yamagami, et al Pemphigus HHS Public access doi:10.1038/nrdp.2017.26. available at: <https://www.ncbi.nlm.nih.gov/pmc/articles/PMC5901732/>
2. Article on pemphigus symptoms and causes published in Mayoclinic on 30 november 2018 available at: <https://www.mayoclinic.org/diseases-conditions/pemphigus/symptoms-causes/syc-20350404>
3. Amagai M, Klaus-Kovtun V, Stanley JR. 'Autoantibodies against a novel epithelial cadherin in pemphigus vulgaris, a disease of cell adhesion.' Cell. 1991;67:869-877.
4. Koch PJ, et al. 'Identification of desmoglein, a constitutive desmosomal glycoprotein, as a member of the cadherin family of cell adhesion molecules'. Eur J Cell Biol. 1990;53:1-12.
5. Alpsoy E, Akman-Karakas A, Uzun S. 'Geographic variations in epidemiology of two autoimmune bullous diseases: pemphigus and bullous pemphigoid.' Arch Dermatol Res. 2015; 307:291-298. [PubMed: 25589418].
6. Shah AA, et al. 'Development of a disease registry for autoimmune bullous diseases: initial analysis of the pemphigus vulgaris subset. Acta Derm Venereol. 2015; 95:86-90. [PubMed: 24691863].
7. Nikhildas et.al 'pemphigus disorders of skin' in Slideshare.net available in link:

- <https://www.slideshare.net/NikhilDas27/pemphigus-disorders-of-skin>
8. Jacquelyn Cafasso, Alana Biggers, MD on 'Pemphigus Vulgaris' on April 19, 2018 available at [:https://www.healthline.com/health/pemphigus-vulgaris#types](https://www.healthline.com/health/pemphigus-vulgaris#types)
 9. Cynthia Cobb, DNP, APRN, Stephanie Watson 'Pemphigus Foliaceus' on July 24, 2017 Available at [:https://www.healthline.com/health/pemphigus-foliaceus](https://www.healthline.com/health/pemphigus-foliaceus)
 10. Article on 'Pemphigus-symptoms and causes' published in Mayo clinic on 30 november 2018 Available at: <https://www.mayoclinic.org/diseases-conditions/pemphigus/diagnosis-treatment/drc-20350409>
 11. Article on 'Pemphigus Foliaceus : what's to know' by Zawn Villines, Suzanne Falck, Available at [:https://www.medicalnewstoday.com/articles/319195.php](https://www.medicalnewstoday.com/articles/319195.php)